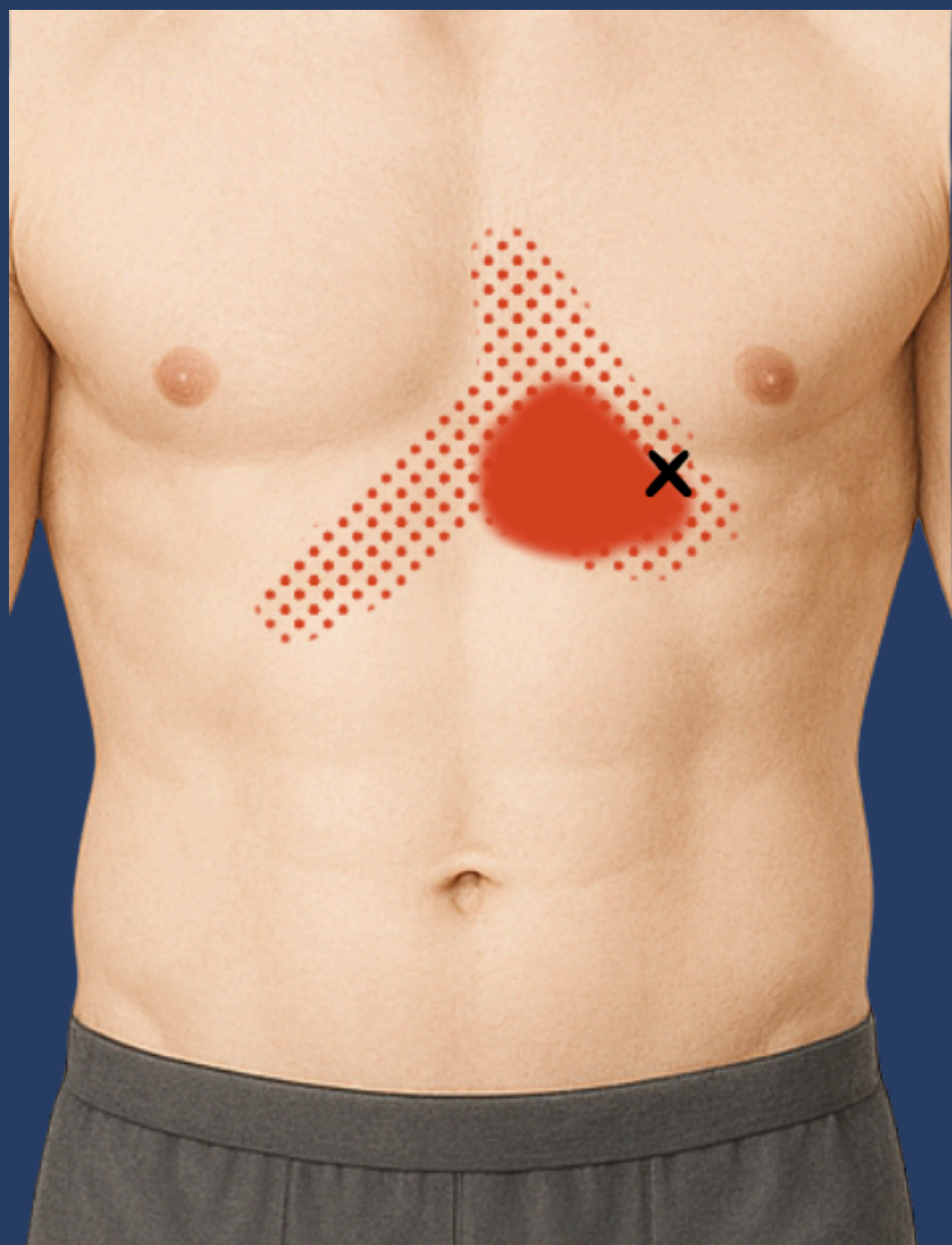
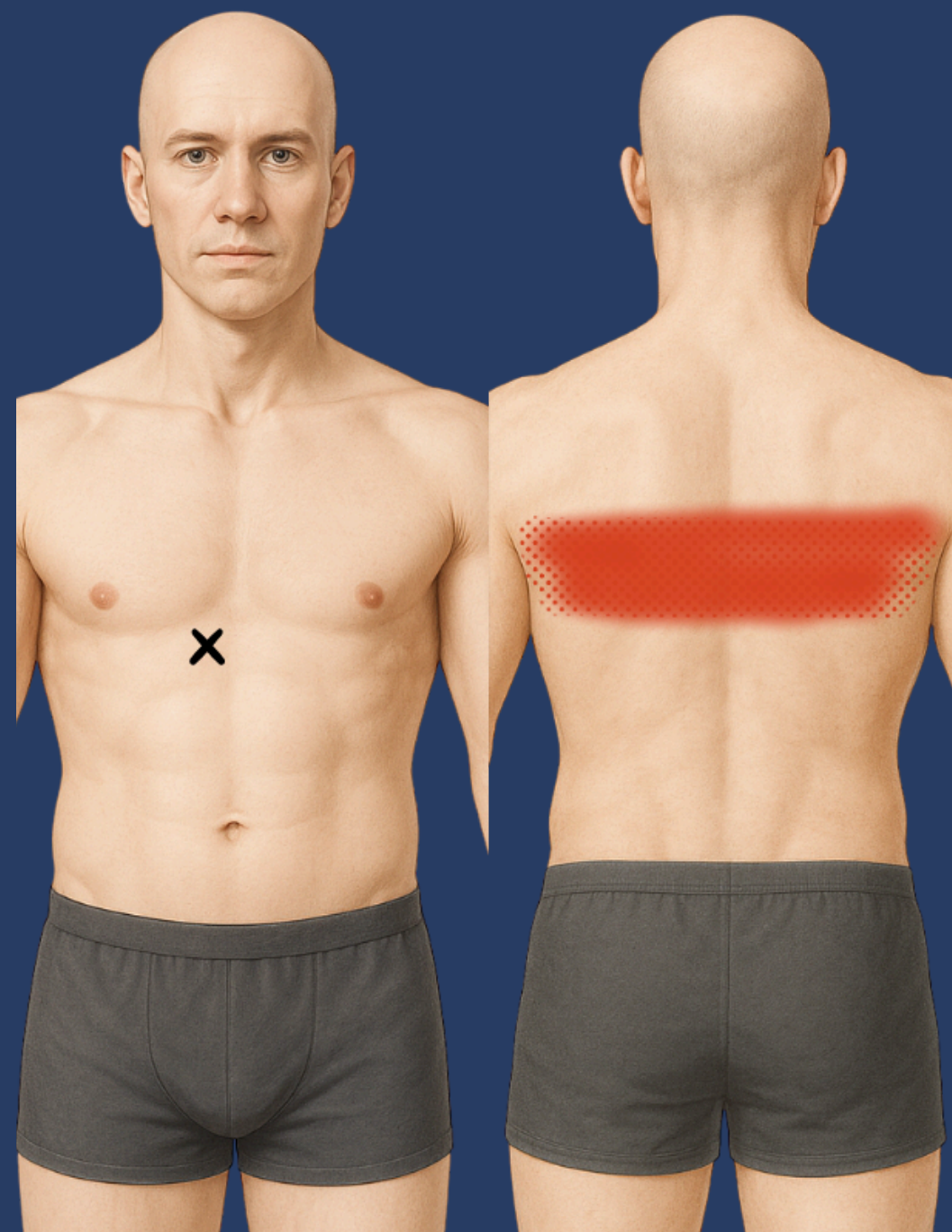


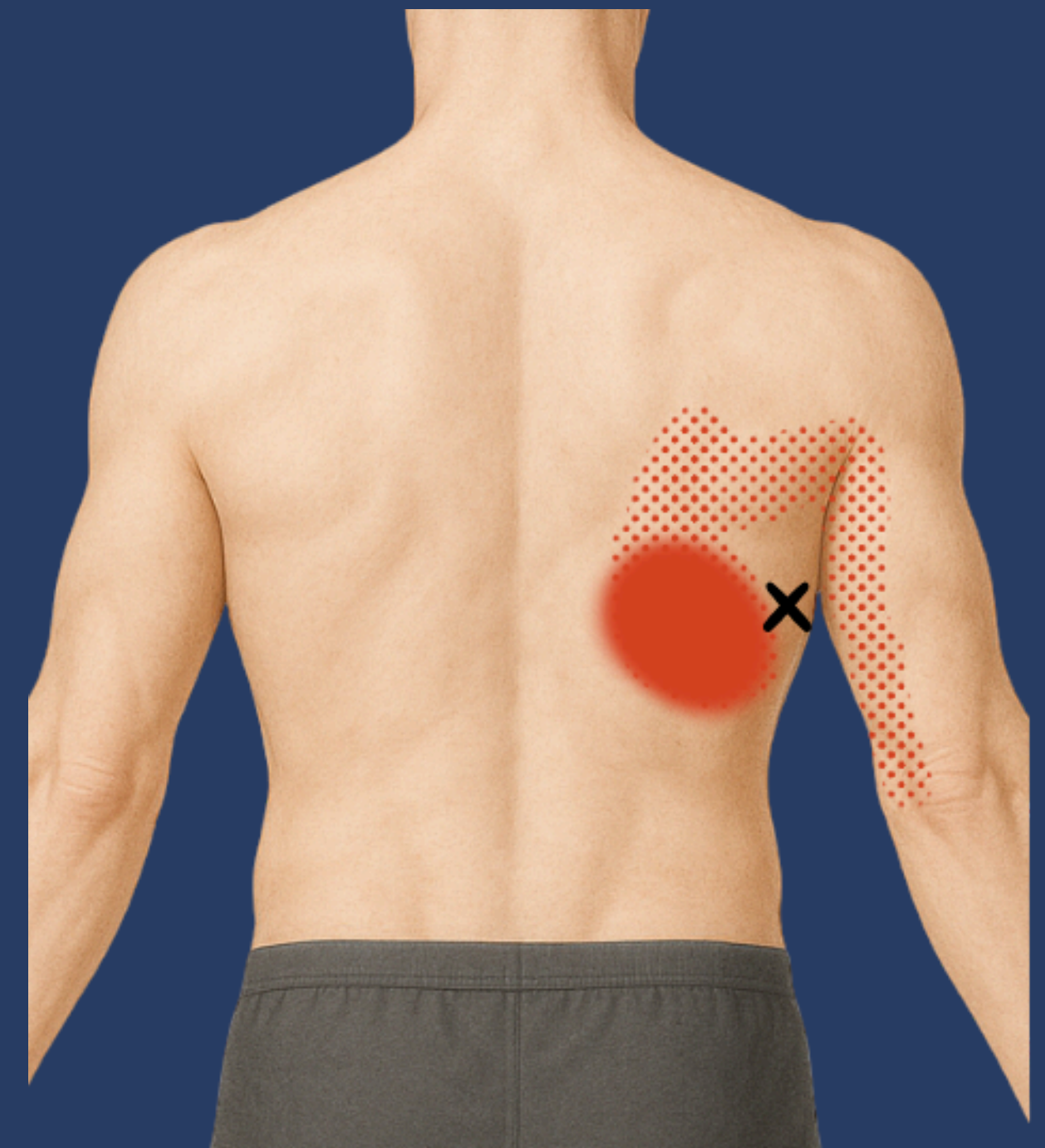
# Région thoracique et dorsale



**OBLIQUE EXTERNE 2**



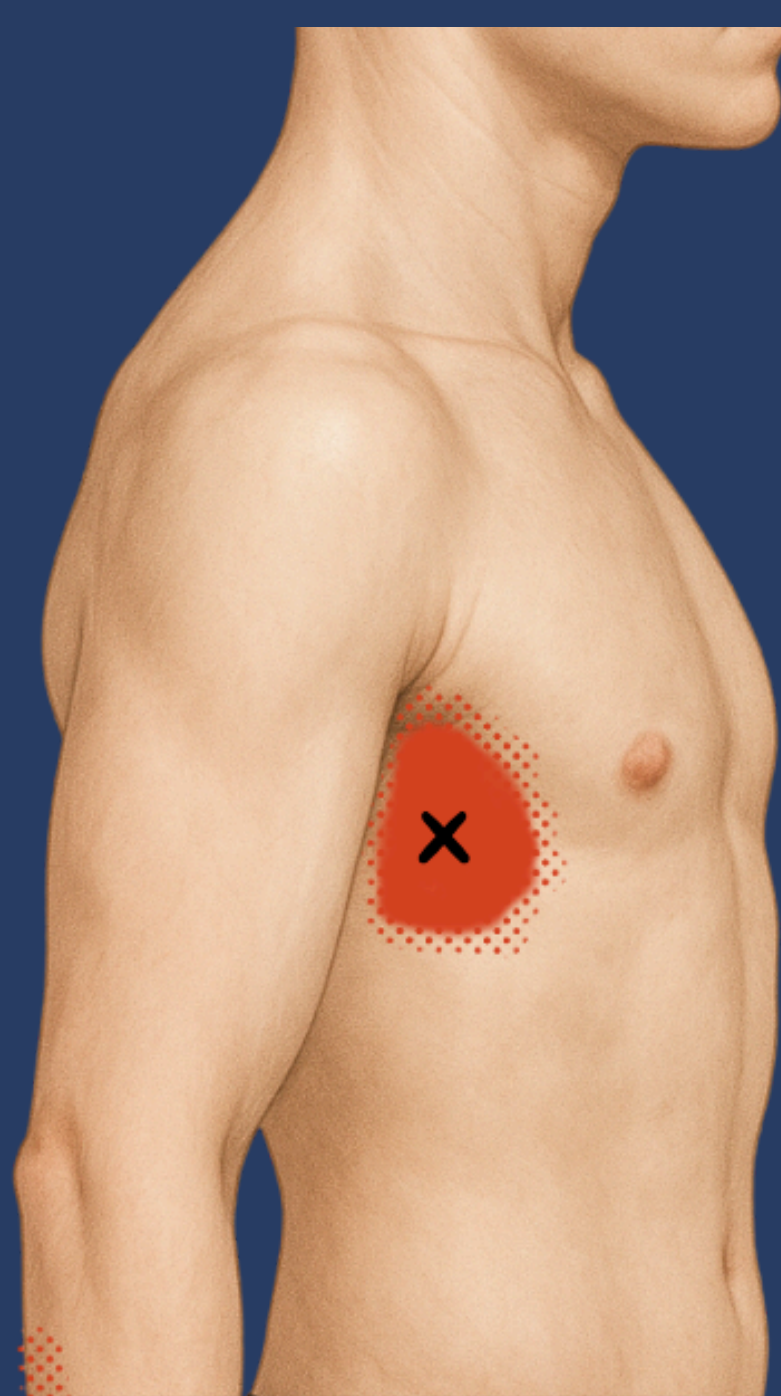
**GRAND DROITS 1**



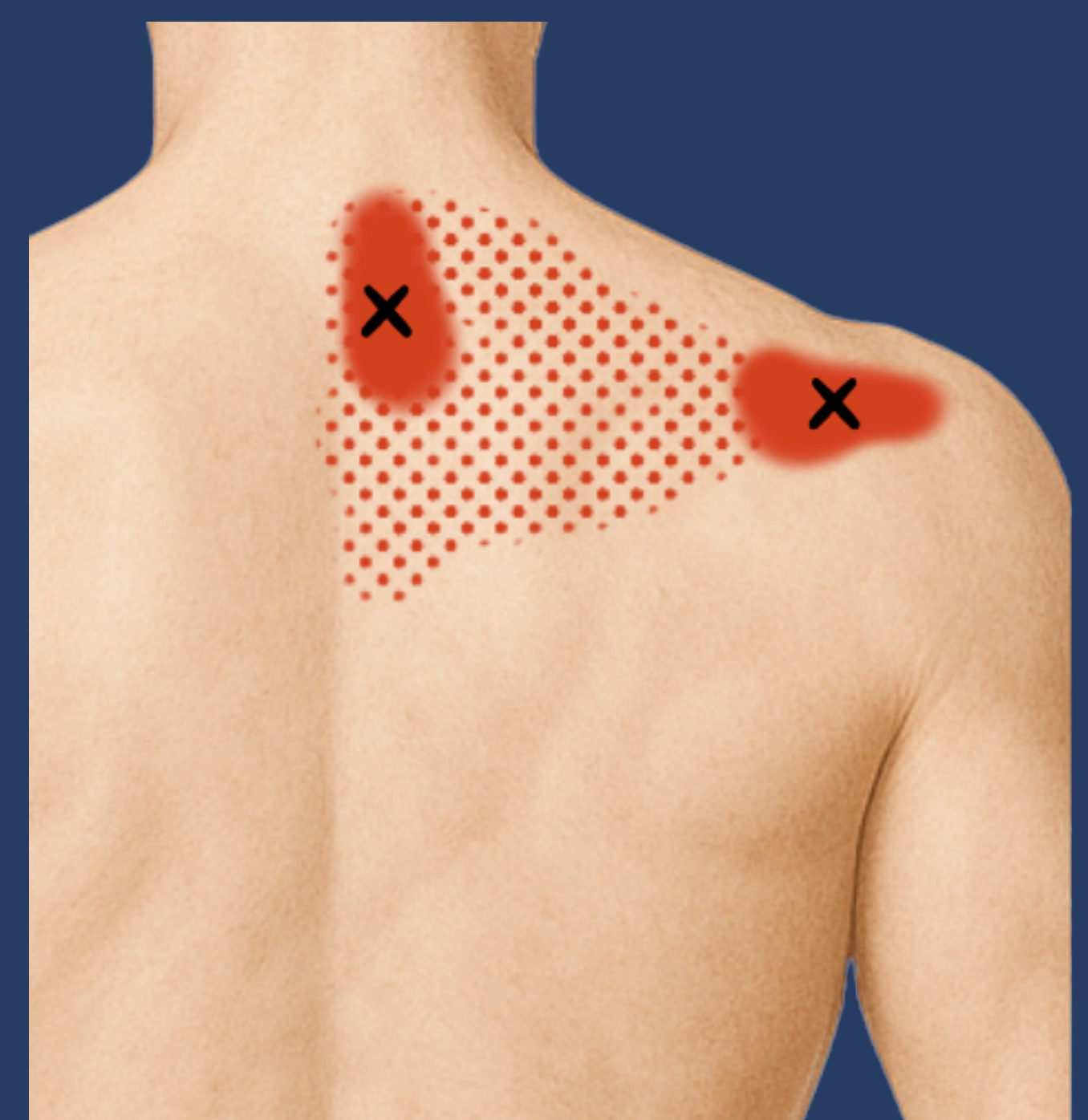
**GRAND DORSAL**



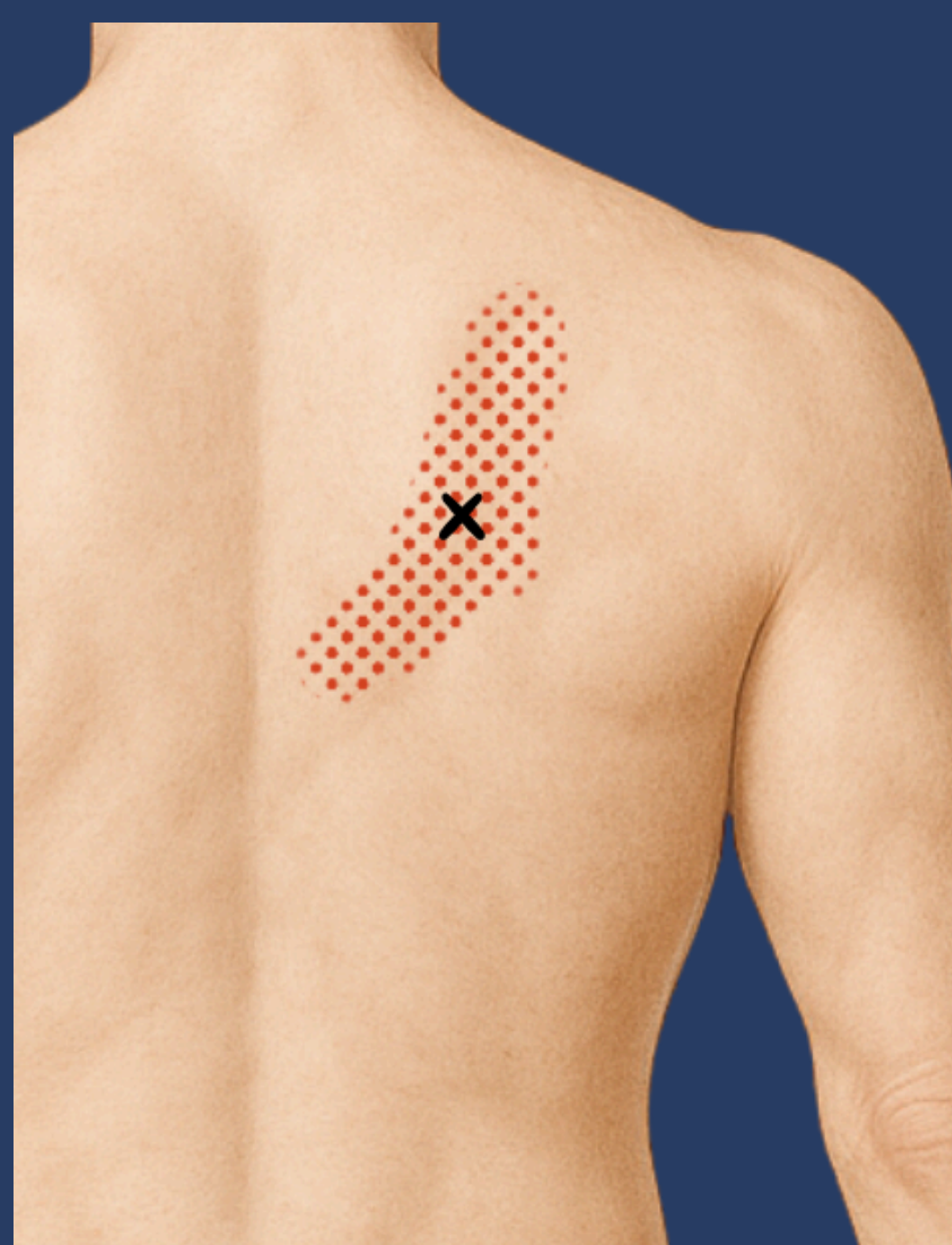
**SERRATUS POSTÉRIEUR  
SUPÉRIEUR**



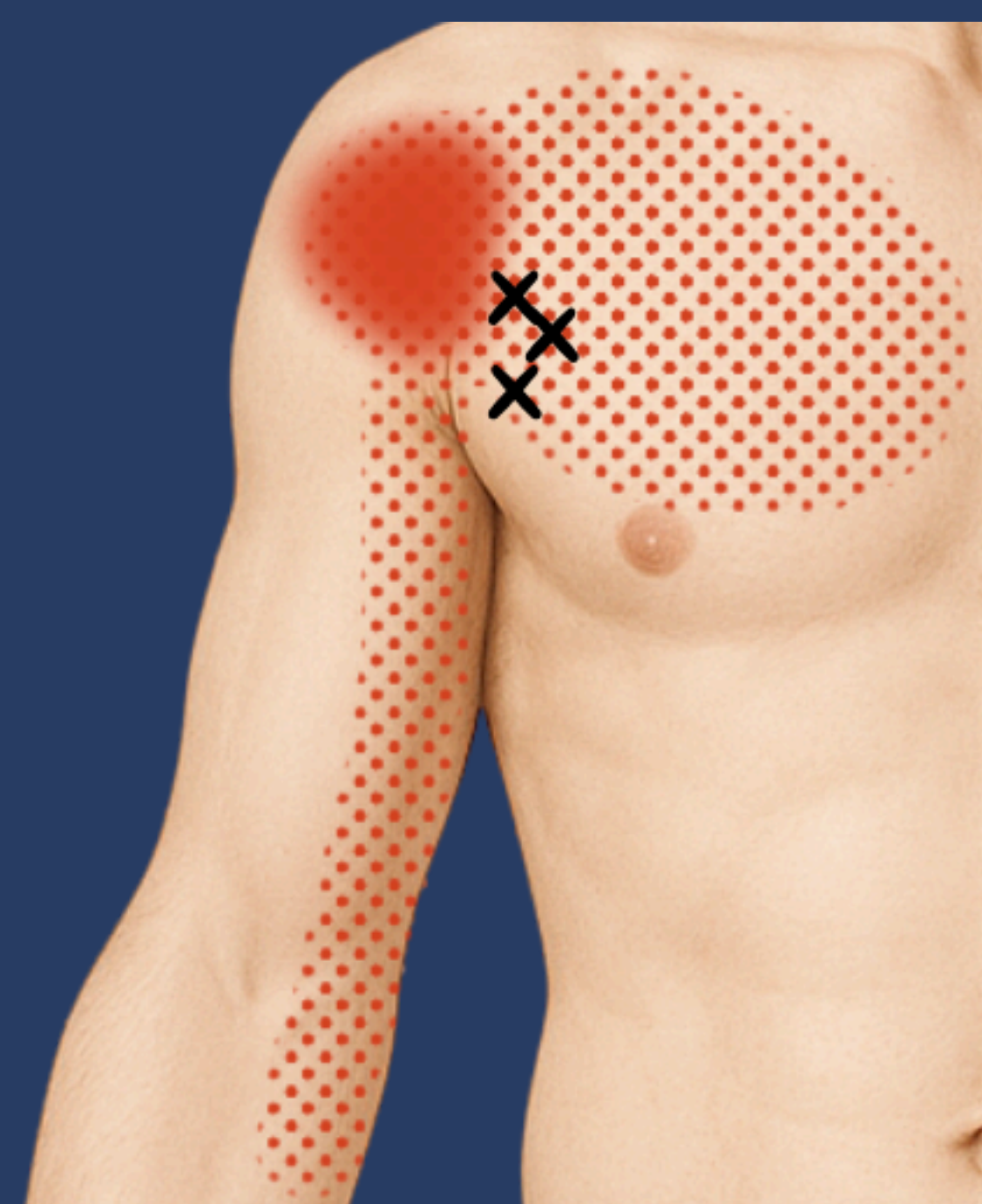
**SUBSCAPULAIRE**



**TRAPÈZE MOYEN**



**RHOMBOÏDE**



**PETIT PECTORAL**